

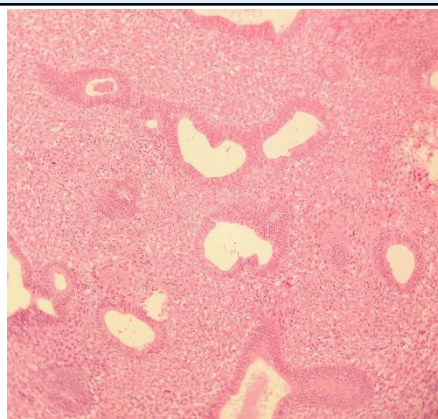
Patient Name	Mrs. PREM SHARMA	Client Name	Lifeaid Wellness Centre,	Specimen Received	21/11/19
Age/Sex	51YRS/F		Gurgaon	Specimen Type	Tissue
Patient ID	011911210338			Collection Date	21/11/19
Specimen ID	MOLQ/B-2200/19			Report Date	25/11/19

SURGICAL PATHOLOGY REPORT

Endometrial polyp with Endometrial curettings

DIAGNOSIS

ENDOMETRIAL POLYP WITH DISORDERED PROLIFERATIVE PHASE



SPECIMEN

Endometrial polyp with Endometrial curettings

GROSS

Received multiple grayish white tissue piece.

Microscopy

1. Section examined shows large number of small endometrial glands with tortuous and cystically dilated gland having cuboidal to columnar lining epithelium with round to oval nucleus.
2. Stroma shows mononuclear inflammatory cells.
3. No granuloma seen. No malignant cells seen.

Note : All biopsy specimen will be stored for 15 (fifteen)days, block and slides for 5(five) years only from the time of receipt at the laboratory. No request ,for any of the above ,will be entertained after the due date.

Reference

- i) Rosai and Ackerman's Surgical Pathology.
- ii) Modern Surgical Pathology.

A handwritten signature in black ink, appearing to read 'Gulshan', written over a light blue rectangular background.

Gulshan Yadav, MD
Consultant Pathologist