

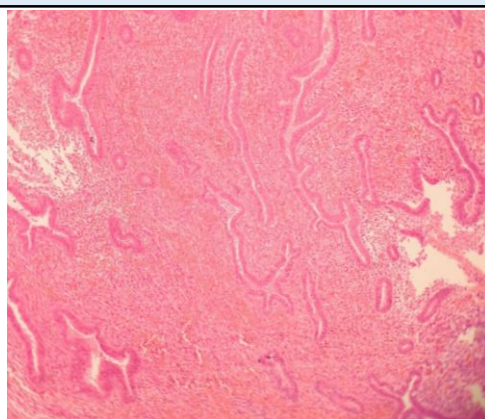
Patient Name	Ms. BABLI	Client Name	Sona Devi Hospital	Specimen Received	23/11/19
Age/Sex	26YRS/F			Specimen Type	Tissue
Patient ID	011911200223			Collection Date	23/11/19
Specimen ID	MOLQ/B-2192/19			Report Date	26/11/19

SURGICAL PATHOLOGY REPORT

Endometrium

DIAGNOSIS

SIMPLE HYPERPLASIA WITHOUT ATYPIA



SPECIMEN

Endometrium

GROSS

Received multiple grayish white tissue piece.

Microscopy

1. Section examined shows small and tortuous endometrial glands with cuboidal lining with small round nucleus.
2. Stroma shows mononuclear inflammatory cells.
3. No granuloma seen. No malignant cells seen.

Note : All biopsy specimen will be stored for 15 (fifteen) days, block and slides for 5 (five) years only from the time of receipt at the laboratory. No request, for any of the above, will be entertained after the due date.

Reference

- i) Rosai and Ackerman's Surgical Pathology.
- ii) Modern Surgical Pathology.

A handwritten signature in black ink, appearing to read 'Gulshan'.

Gulshan Yadav, MD
Consultant Pathologist