

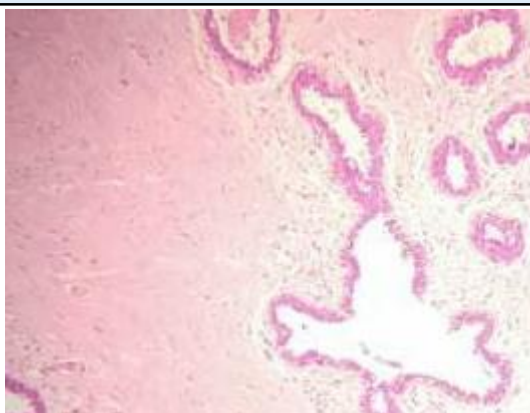
Patient Name	Ms. SAYAMA BANO	Client Name	Apollo Laboratories CC, J &K	Specimen Received	20/11/19
Age/Sex	25YRS/F			Specimen Type	Tissue
Patient ID	011911200347			Collection Date	20/11/19
Specimen ID	MOLQ/B-2195/19			Report Date	23/11/19

SURGICAL PATHOLOGY REPORT

Breast (Left)

DIAGNOSIS

BENIGN BREAST LESION



SPECIMEN

Breast (Left)

GROSS

Received multiple greyish white tissue piece, measuring 3x3 cm in aggregate.

Microscopy

Section examined shows ducts (few cystically dilated) with cuboidal epithelium with small round nucleus. surrounded by fibro collagenous tissue.

No granuloma seen. No malignant cells seen.

Note : All biopsy specimen will be stored for 15 (fifteen)days, block and slides for 5(five) years only from the time of receipt at the laboratory. No request ,for any of the above ,will be entertained after the due date.

Reference

- i) Rosai and Ackerman's Surgical Pathology.
- ii) Modern Surgical Pathology.

Gulshan Yadav, MD
Consultant Pathologist