

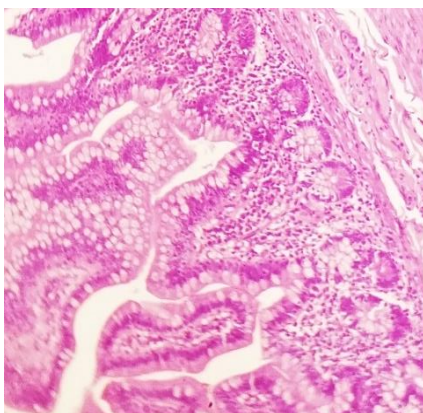
Patient Name	Mr. GH MOHIUDIN	Client Name	Apollo Laboratories CC, J & K	Specimen Received	20/11/19
Age/Sex	45YRS/M			Specimen Type	Tissue
Patient ID	011911200343			Collection Date	20/11/19
Specimen ID	MOLQ/B-2194/19			Report Date	23/11/19

SURGICAL PATHOLOGY REPORT

Appendix with Meckels Diverticulum

DIAGNOSIS

ACUTE APPENDICITIS WITH MECKELS DIVERTICULUM



SPECIMEN

Appendix with Meckels Diverticulum

GROSS

Received two tissue pieces,
 1) 6.7x1 cm long appendix. Cut section shows fecolith.
 2) 2x2.3 cm long greyish white tissue piece.

Microscopy

Section examined shows lymphoid follicles with ulcerative mucosa. Deeper tissue shows inflammatory cells (polymorphs and lymphocytes). No granuloma seen. No malignant cells seen. Section also shows mucosal lining epithelium with villi having columnar lining epithelium with round to oval nucleus, submucosal glands. Deeper tissue shows fibrocollagenous tissue, blood vessels and muscle bundles.
 No granuloma seen. No malignant cells seen.

Note : All biopsy specimen will be stored for 15 (fifteen) days, block and slides for 5 (five) years only from the time of receipt at the laboratory. No request, for any of the above, will be entertained after the due date.

Reference

- i) Rosai and Ackerman's Surgical Pathology.
- ii) Modern Surgical Pathology.

Gulshan Yadav, MD
Consultant Pathologist