

Patient Name	Mrs. SUNITA DEVI	Client Name	Chiranjeev Path Lab	Specimen Received	20/11/19
Age/Sex	35YRS/F			Specimen Type	Tissue
Patient ID	011911200071			Collection Date	20/11/19
Specimen ID	MOLQ/B-2188/19			Report Date	23/11/19

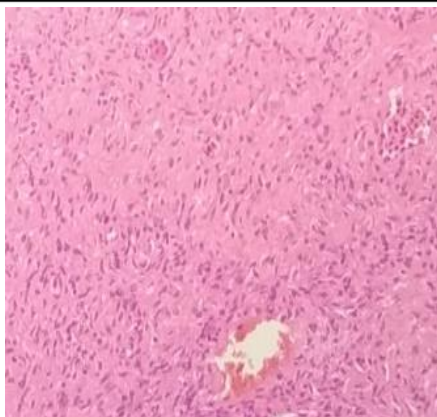
SURGICAL PATHOLOGY REPORT

Ovarian Cyst (Left)

DIAGNOSIS

HEMORRHAGIC CYST

ADVISED: Kindly, co-relate with clinical findings.



SPECIMEN

Ovarian Cyst (Left)

GROSS

Received 3.5x2 cm ovary with tube. Cut section shows 1x1 cm cyst with clear fluid.

Microscopy

Section examined shows ovarian tissue with hemorrhagic area.

No granuloma seen. No malignant cells seen.

Tube is unremarkable.

Note : All biopsy specimen will be stored for 15 (fifteen) days, block and slides for 5 (five) years only from the time of receipt at the laboratory. No request, for any of the above, will be entertained after the due date.

Reference

- i) Rosai and Ackerman's Surgical Pathology.
- ii) Modern Surgical Pathology.

Gulshan Yadav, MD
Consultant Pathologist