

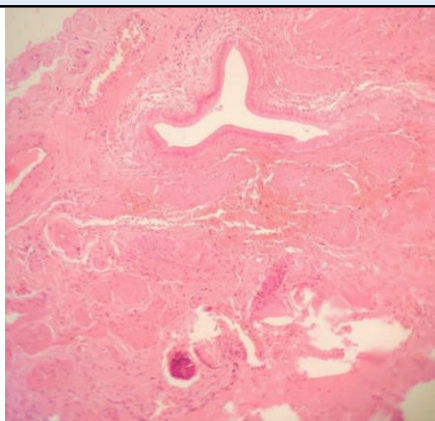
Patient Name	Ms. USHA ARYA	Client Name	Goyal Nursing Home (Palwal)	Specimen Received	19/11/19
Age/Sex	53 YRS/M			Specimen Type	Tissue
Patient ID	011911190251			Collection Date	19/11/19
Specimen ID	MOLQ/B-2186/19			Report Date	22/11/19

SURGICAL PATHOLOGY REPORT

Gall Bladder

DIAGNOSIS

CHOLECYSTITIS AND CHOLELITHIASIS.



SPECIMEN

Gall Bladder

GROSS

Received 8x3 cm long gall bladder already cut open with stones. Wall Thickness 0.3 mm.

Microscopy

- Section examined shows ulcerative mucosa and rokitansky aschoff sinus (irregularly shaped tubular structures lined by cuboidal lining epithelium with round to oval nucleus) with fibro collagenous tissue and inflammatory cells (lymphocytes).

Note : All biopsy specimen will be stored for 15 (fifteen)days, block and slides for 5(five) years only from the time of receipt at the laboratory. No request ,for any of the above ,will be entertained after the due date.

Reference

- Rosai and Ackerman's Surgical Pathology.
- Modern Surgical Pathology.

Gulshan Yadav, MD
Consultant Pathologist