

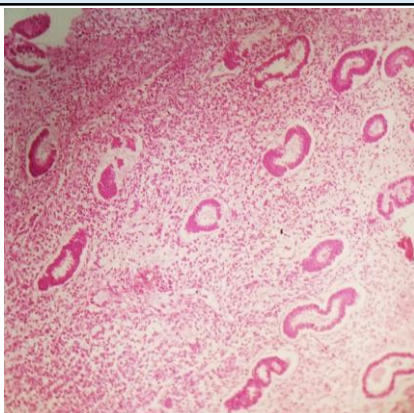
Patient Name	Mrs. KIRAN	Client Name	Civil Hospital Sec-10	Specimen Received	19/11/19
Age/Sex	40 Years/Female			Specimen Type	Tissue
Patient ID	011911190161			Collection Date	19/11/19
Specimen ID	MOLQ/B-2184/19			Report Date	22/11/19

SURGICAL PATHOLOGY REPORT

Endometrium

DIAGNOSIS

DISORDERED PROLIFERATIVE PHASE



SPECIMEN

Endometrium

GROSS

Received multiple grayish white tissue piece.

Microscopy

1. Section examined shows small and tortuous endometrial glands with cuboidal to columnar lining with small round to oval nucleus with vacuolization.
2. Stroma shows mononuclear inflammatory cells.
3. No granuloma seen. No malignant cells seen.

Note : All biopsy specimen will be stored for 15 (fifteen) days, block and slides for 5 (five) years only from the time of receipt at the laboratory. No request, for any of the above, will be entertained after the due date.

Reference

- i) Rosai and Ackerman's Surgical Pathology.
- ii) Modern Surgical Pathology.

Gulshan Yadav, MD
Consultant Pathologist