

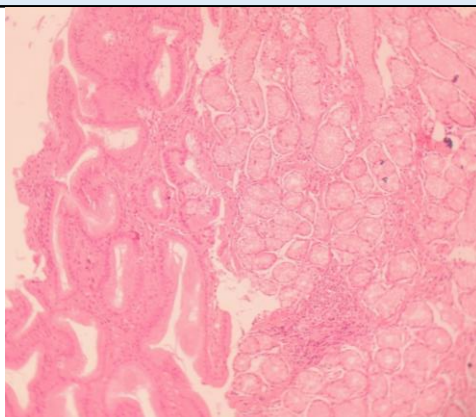
<b>Patient Name</b>	Ms. RUBEENA	<b>Client Name</b>	Faith Clinical Laboratory	<b>Specimen Received</b>	17/11/19
<b>Age/Sex</b>	26YRS/F		Jammu & Kashmir	<b>Specimen Type</b>	Tissue
<b>Patient ID</b>	011911170263			<b>Collection Date</b>	17/11/19
<b>Specimen ID</b>	MOLQ/B-2178/19			<b>Report Date</b>	21/11/19

## SURGICAL PATHOLOGY REPORT

### Prepyloric Ulcer

#### DIAGNOSIS

NON-SPECIFIC INFLAMMATION.



#### SPECIMEN

Prepyloric Ulcer

#### GROSS

Received tiny grayish white tissue piece.

#### Microscopy

1. Section examined shows mucosal lining epithelium with columnar cells having round to oval nucleus.
2. Section also shows submucosal glands with mononuclear inflammatory cells.
3. No granuloma seen. No malignant cells seen.

**Note :** All biopsy specimen will be stored for 15 (fifteen)days, block and slides for 5(five) years only from the time of receipt at the laboratory. No request ,for any of the above ,will be entertained after the due date.

#### Reference

- i) Rosai and Ackerman's Surgical Pathology.
- ii) Modern Surgical Pathology.



**Gulshan Yadav, MD**  
Consultant Pathologist