

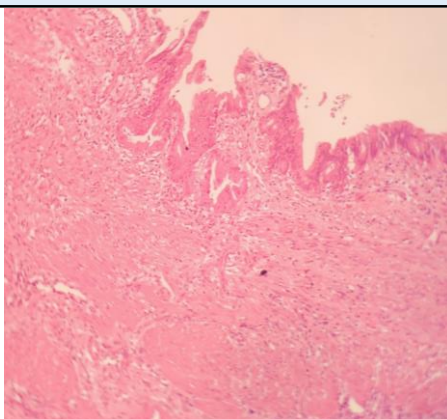
Patient Name	Mrs. SHANTI DEVI	Client Name	Galaxy Hospital, Palwal)	Specimen Received	16/11/19
Age/Sex	54YRS/F			Specimen Type	Tissue
Patient ID	011911160255			Collection Date	16/11/19
Specimen ID	MOLQ/B-2172/19			Report Date	21/11/19

SURGICAL PATHOLOGY REPORT

Gall Bladder

DIAGNOSIS

CHOLECYSTITIS AND CHOLELITHIASIS.



SPECIMEN

Gall Bladder

GROSS

Received 5.5x3.9 cm long gall bladder already cut open with stones. Wall thickness 0.6 mm.

Microscopy

- Section examined shows ulcerative mucosa and Rokitansky-Aschoff sinuses (irregularly shaped tubular structures lined by cuboidal lining epithelium with round to oval nucleus) with fibro collagenous tissue and inflammatory cells (lymphocytes).

Note : All biopsy specimen will be stored for 15 (fifteen) days, block and slides for 5 (five) years only from the time of receipt at the laboratory. No request, for any of the above, will be entertained after the due date.

Reference

- Rosai and Ackerman's Surgical Pathology.
- Modern Surgical Pathology.

Gulshan Yadav, MD
Consultant Pathologist