

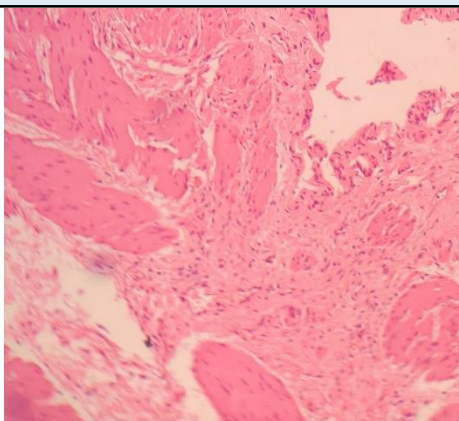
Patient Name	Mr. LAXMI NARAYAN	Client Name	Goyal Nursing Home (Palwal)	Specimen Received	16/11/19
Age/Sex	55YRS/M			Specimen Type	Tissue
Patient ID	011911160250			Collection Date	16/11/19
Specimen ID	MOLQ/B-2171/19			Report Date	21/11/19

SURGICAL PATHOLOGY REPORT

Cyst Scrotum (Left)

DIAGNOSIS

BENIGN MESENCHYMAL LESION.



SPECIMEN

Cyst Scrotum (Left)

GROSS

Received 2x3 cm grayish white tissue piece.

Microscopy

1. Section examined shows fibrocollagenous tissue, mature adipose cells, blood vessels with cuboidal lining epithelium having round to oval nucleus.
2. No granuloma seen. No malignant cells seen.

Note : All biopsy specimen will be stored for 15 (fifteen) days, block and slides for 5 (five) years only from the time of receipt at the laboratory. No request, for any of the above, will be entertained after the due date.

Reference

- i) Rosai and Ackerman's Surgical Pathology.
- ii) Modern Surgical Pathology.



Gulshan Yadav, MD
Consultant Pathologist