

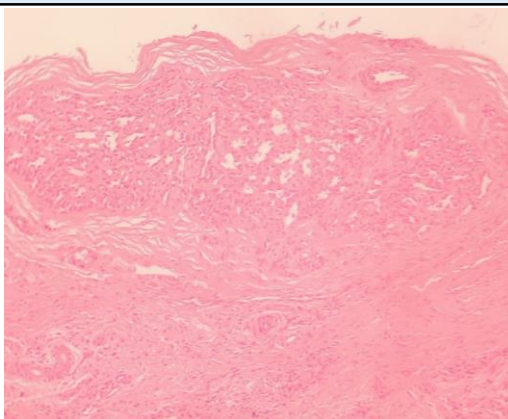
<b>Patient Name</b>	Mr. RAHUL	<b>Client Name</b>	MolQ Collection Centre	<b>Specimen Received</b>	16/11/19
<b>Age/Sex</b>	28YRS/M		CSK Hospita, Sohna	<b>Specimen Type</b>	Tissue
<b>Patient ID</b>	011911160149			<b>Collection Date</b>	16/11/19
<b>Specimen ID</b>	MOLQ/B-2175/19			<b>Report Date</b>	21/11/19

## SURGICAL PATHOLOGY REPORT

### Sebaceous Cyst (Left forearm)

#### DIAGNOSIS

BENIGN MESENCHYMAL LESION.



#### SPECIMEN

Sebaceous Cyst (Left forearm)

#### GROSS

Received 1x1 cm grayish white tissue piece, 5x4 cm in aggregate. Cut section show blood clot.

#### Microscopy

1. Section examined shows fibrocollagenous tissue surrounded by mature adipose cells. Lumen shows large number of RBCs.
2. No granuloma seen. No malignant cells seen.

**Note :** All biopsy specimen will be stored for 15 (fifteen)days, block and slides for 5(five) years only from the time of receipt at the laboratory. No request ,for any of the above ,will be entertained after the due date.

#### Reference

- i) Rosai and Ackerman's Surgical Pathology.
- ii) Modern Surgical Pathology.

**Gulshan Yadav, MD**  
Consultant Pathologist