

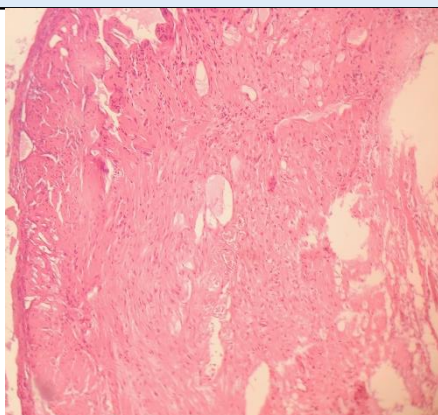
Patient Name	Mr. ABHISHEK	Client Name	Shri Balaji Multispeciality Hospital-Gurgaon	Specimen Received	16/11/19
Age/Sex	13YRS/M			Specimen Type	Tissue
Patient ID	011911160125			Collection Date	16/11/19
Specimen ID	MOLQ/B-2168/19			Report Date	21/11/19

SURGICAL PATHOLOGY REPORT

Appendix

DIAGNOSIS

ACUTE APPENDICITIS



SPECIMEN

Appendix

GROSS

Received 3.9x1.8 cm long appendix. Cut section shows feco-lith.

Microscopy

1. Section examined shows lymphoid follicles with ulcerative mucosa. Deeper tissue shows inflammatory cells (polymorphs and lymphocytes) and dystrophic calcifications.
2. No granuloma seen. No malignant cells seen.

Note : All biopsy specimen will be stored for 15 (fifteen)days, block and slides for 5(five) years only from the time of receipt at the laboratory. No request ,for any of the above ,will be entertained after the due date.

Reference

- i) Rosai and Ackerman's Surgical Pathology.
- ii) Modern Surgical Pathology.

Gulshan Yadav, MD
Consultant Pathologist