

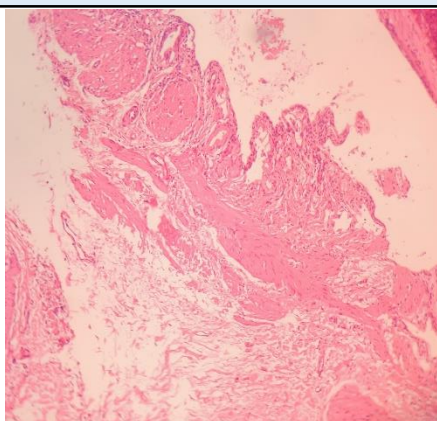
Patient Name	Mrs. ARJUMA BIBI	Client Name	Lifeaid Wellness Centre	Specimen Received	16/11/19
Age/Sex	45YRS/f			Specimen Type	Tissue
Patient ID	011911160080			Collection Date	16/11/19
Specimen ID	MOLQ/B-2167/19			Report Date	21/11/19

SURGICAL PATHOLOGY REPORT

Gall Bladder

DIAGNOSIS

CHOLECYSTITIS.



SPECIMEN

Gall Bladder

GROSS

Received 6.8x2.8 cm long gall bladder already cut open without stones. Wall Thickness 0.6 mm. fluid and blood clot.

Microscopy

1. Section examined shows ulcerative mucosa and Rokitansky Aschoff sinus (irregularly shaped tubular structures lined by cuboidal lining epithelium with round to oval nucleus) with fibrocollagenous tissue and inflammatory cells (lymphocytes).

Note : All biopsy specimen will be stored for 15 (fifteen) days, block and slides for 5 (five) years only from the time of receipt at the laboratory. No request, for any of the above, will be entertained after the due date.

Reference

- i) Rosai and Ackerman's Surgical Pathology.
- ii) Modern Surgical Pathology.

Gulshan Yadav, MD
Consultant Pathologist