

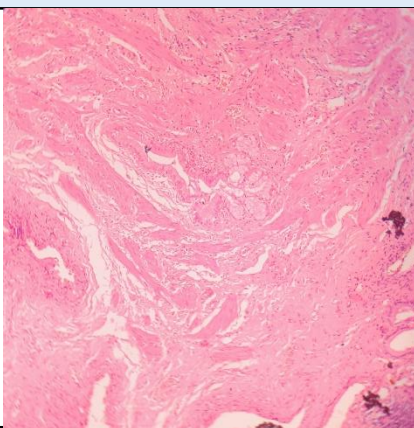
Patient Name	Mr. SATENDER	Client Name	Cygnus SuperSpeciality	Specimen Received	15/11/19
Age/Sex	31YRS/M		Hospital, Rewari	Specimen Type	Tissue
Patient ID	011911150277			Collection Date	15/11/19
Specimen ID	MOLQ/B-2159/19			Report Date	20/11/19

SURGICAL PATHOLOGY REPORT

Appendix

DIAGNOSIS

ACUTE APPENDICITIS



SPECIMEN

Appendix

GROSS

Received autolyzed 1x1 cm long appendix with mesoappendix. Cut section shows feco-lith.

Microscopy

1. Section examined shows lymphoid follicles with ulcerative mucosa.
2. Deeper tissue shows inflammatory cells (polymorphs and lymphocytes).
3. No granuloma seen.
4. No malignant cells seen.

Note : All biopsy specimen will be stored for 15 (fifteen)days, block and slides for 5(five) years only from the time of receipt at the laboratory. No request ,for any of the above ,will be entertained after the due date.

Reference

- i) Rosai and Ackerman's Surgical Pathology.
- ii) Modern Surgical Pathology.

Gulshan Yadav, MD
Consultant Pathologist