

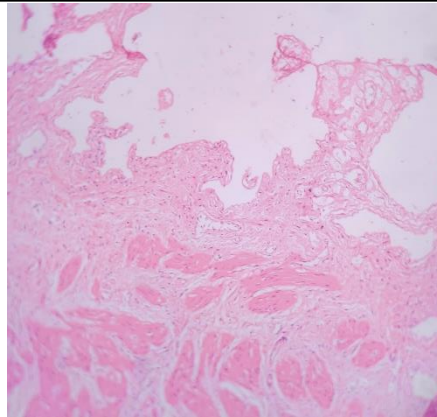
Patient Name	Mrs. SANGEETA	Client Name	Civil Hospital Sec-10	Specimen Received	15/11/19
Age/Sex	33YRS/F			Specimen Type	Tissue
Patient ID	011911150162			Collection Date	15/11/19
Specimen ID	MOLQ/B-2157/19			Report Date	20/11/19

SURGICAL PATHOLOGY REPORT

Gall Bladder

DIAGNOSIS

CHOLECYSTITIS AND CHOLELITHIASIS.



SPECIMEN

Gall Bladder

GROSS

Received 5.2x2.1 cm long gall bladder. Cut section shows stones.


Microscopy

1. Section examined shows ulcerative mucosa and Rokitansky-Aschoff sinuses (irregularly shaped tubular structures lined by cuboidal lining epithelium with round to oval nucleus) with fibrocollagenous tissue and inflammatory cells (lymphocytes).

Note : All biopsy specimen will be stored for 15 (fifteen) days, block and slides for 5 (five) years only from the time of receipt at the laboratory. No request, for any of the above, will be entertained after the due date.

Reference

- i) Rosai and Ackerman's Surgical Pathology.
- ii) Modern Surgical Pathology.


Gulshan Yadav, MD
Consultant Pathologist