

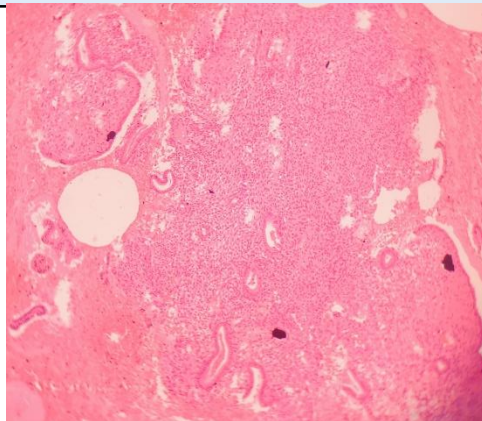
<b>Patient Name</b>	Mrs. SHIMLA DEVI	<b>Client Name</b>	Chiranjivi Diagnostic	<b>Specimen Received</b>	14/11/19
<b>Age/Sex</b>	29 YRS/F		Jharsa	<b>Specimen Type</b>	Tissue
<b>Patient ID</b>	011911140343			<b>Collection Date</b>	14/11/19
<b>Specimen ID</b>	MOLQ/B-2154/19			<b>Report Date</b>	19/11/19

## SURGICAL PATHOLOGY REPORT

### Endometrium

#### DIAGNOSIS

PROLIFERATIVE PHASE



#### SPECIMEN

Endometrium

#### GROSS

Received multiple grayish white tissue piece.


#### Microscopy

1. Section examined shows small endometrial glands with cuboidal lining with small round nucleus. Stroma shows mononuclear inflammatory cells, fibrin and RBCs.
2. No granuloma seen. No malignant cells seen.

**Note :** All biopsy specimen will be stored for 15 (fifteen) days, block and slides for 5 (five) years only from the time of receipt at the laboratory. No request, for any of the above, will be entertained after the due date.

#### Reference

- i) Rosai and Ackerman's Surgical Pathology.
- ii) Modern Surgical Pathology.

  
**Gulshan Yadav, MD**  
Consultant Pathologist