

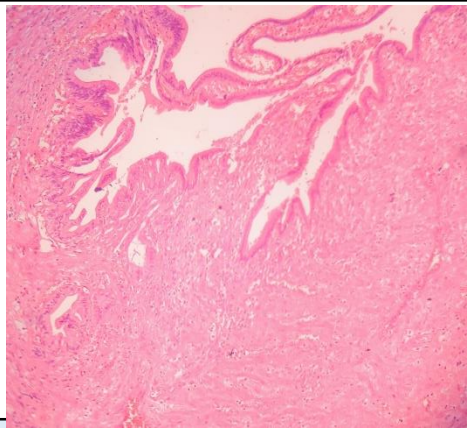
Patient Name	Ms. BHANI DEVI	Client Name	S. M. Diagnostics, Kaithal	Specimen Received	13/11/19
Age/Sex	58`YRS/F			Specimen Type	Tissue
Patient ID	011911130036			Collection Date	13/11/19
Specimen ID	MOLQ/B-2138/19			Report Date	19/11/19

SURGICAL PATHOLOGY REPORT

Gall Bladder

DIAGNOSIS

CHOLECYSTITIS AND CHOLELITHIASIS.



SPECIMEN

Gall Bladder

GROSS

Received 10.4x4.1 cm long gall bladder already cut open with tiny stones. Wall Thickness 0.3 mm.


Microscopy

1. Section examined shows ulcerative mucosa and Rokitansky-Aschoff sinuses (irregularly shaped tubular structures lined by cuboidal lining epithelium with round to oval nucleus) with fibrocollagenous tissue and inflammatory cells (lymphocytes).

Note : All biopsy specimen will be stored for 15 (fifteen) days, block and slides for 5 (five) years only from the time of receipt at the laboratory. No request, for any of the above, will be entertained after the due date.

Reference

- i) Rosai and Ackerman's Surgical Pathology.
- ii) Modern Surgical Pathology.


Gulshan Yadav, MD
Consultant Pathologist