

<b>Patient Name</b>	<b>Mr. ARSAD KHAN</b>	<b>Client Name</b>	Dinesh Lab, Bhiwari	<b>Specimen Received</b>	12/11/19
<b>Age/Sex</b>	28 Years/Male			<b>Specimen Type</b>	Tissue
<b>Patient ID</b>	011911120251			<b>Collection Date</b>	12/11/19
<b>Specimen ID</b>	MOLQ/B-2136/19			<b>Report Date</b>	19/11/19

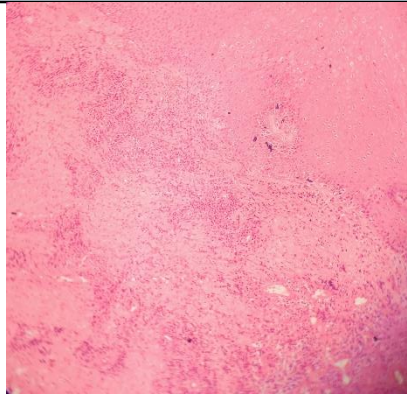
## SURGICAL PATHOLOGY REPORT

### Left Subcutaneous Swelling in Scrotum

#### DIAGNOSIS

#### CHRONIC INFECTIVE LESION

**ADVISED: AFB culture and TB-PCR from Pus.**



#### SPECIMEN

Left Subcutaneous Swelling in Scrotum

#### GROSS

Received two grayish white tissue piece 1x1 cm, 0.5x0.5 cm.


#### Microscopy

1. Section examined shows squamous lining epithelium with round to oval nucleus.
2. Deeper tissue shows large number of inflammatory cells (plasmacytoid cells, histiocytes, lymphocytes), fibrocollagneous tissue and blood vessels.
3. No malignant cells seen.

**Note :** All biopsy specimen will be stored for 15 (fifteen)days, block and slides for 5(five) years only from the time of receipt at the laboratory. No request ,for any of the above ,will be entertained after the due date.

#### Reference

- i) Rosai and Ackerman's Surgical Pathology.
- ii) Modern Surgical Pathology.

  
**Gulshan Yadav, MD**  
Consultant Pathologist