

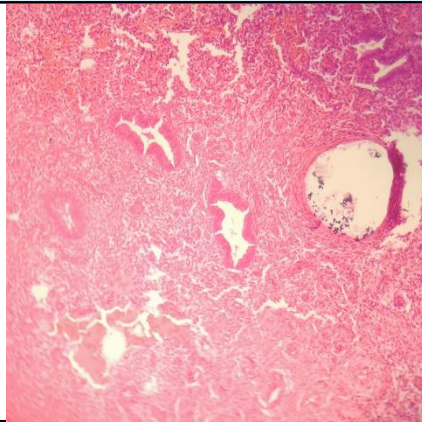
<b>Patient Name</b>	<b>Mrs. BIRMATI 1947</b>	<b>Client Name</b>	Pushpanjali Hospital (Rewari)	<b>Specimen Received</b>	11/11/19
<b>Age/Sex</b>	56 Years/Female			<b>Specimen Type</b>	Tissue
<b>Patient ID</b>	011911110211			<b>Collection Date</b>	11/11/19
<b>Specimen ID</b>	MOLQ/B-2128/19			<b>Report Date</b>	18/11/19

## SURGICAL PATHOLOGY REPORT

### Endometrium (Thickened)

#### DIAGNOSIS

**PROLIFERATIVE PHASE WITH SIMPLE HYPERPLASIA WITHOUT ATYPIA.**



#### SPECIMEN

Endometrium (Thickened)

#### GROSS

Received multiple grayish white tissue piece.


#### Microscopy

1. Section examined shows few small and broken endometrial glands with occasional cystically dilated glands with cuboidal to columnar lining with small round nucleus.
2. Stroma shows mononuclear inflammatory cells and fibrin.
3. No granuloma seen. No malignant cells seen.

**Note :** All biopsy specimen will be stored for 15 (fifteen) days, block and slides for 5 (five) years only from the time of receipt at the laboratory. No request, for any of the above, will be entertained after the due date.

#### Reference

- i) Rosai and Ackerman's Surgical Pathology.
- ii) Modern Surgical Pathology.

  
**Gulshan Yadav, MD**  
Consultant Pathologist