

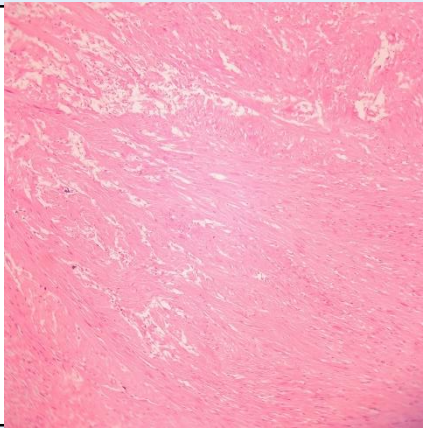
Patient Name	Mrs. USHA	Client Name	Life Care Path Lab, Tauru)	Specimen Received	11/11/19
Age/Sex	44 YRS/F			Specimen Type	Tissue
Patient ID	011911110109			Collection Date	11/11/19
Specimen ID	MOLQ/B-2123/19			Report Date	18/11/19

SURGICAL PATHOLOGY REPORT

Left Post Auricular Swelling

DIAGNOSIS

BENIGN MESENCHYMAL LESION.



SPECIMEN

Left Post Auricular Swelling

GROSS

Received 3.5x2.0 grayish white tissue piece.

Microscopy

1. Section examined shows fibrocollagenous tissue arranged in fascicles, interlacing muscle bundles with spindle shaped nucleus.
2. No granuloma seen.
3. No malignant cells seen.

Note : All biopsy specimen will be stored for 15 (fifteen) days, block and slides for 5 (five) years only from the time of receipt at the laboratory. No request, for any of the above, will be entertained after the due date.

Reference

- i) Rosai and Ackerman's Surgical Pathology.
- ii) Modern Surgical Pathology.



Gulshan Yadav, MD
Consultant Pathologist