

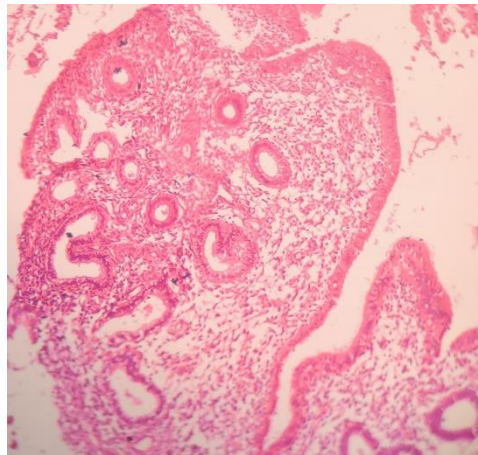
<b>Patient Name</b>	<b>Mrs. SATYAWANTI</b>	<b>Client Name</b>	Brijanand Path Lab	<b>Specimen Received</b>	10-Nov-2019
<b>Age/Sex</b>	50 Years/Female			<b>Specimen Type</b>	Tissue
<b>Patient ID</b>	011911100179			<b>Collection Date</b>	10-Nov-2019
<b>Specimen ID</b>	MOLQ/B-2118/19			<b>Report Date</b>	10-Nov-2019

## SURGICAL PATHOLOGY REPORT

Endometrial Curettings

### DIAGNOSIS

**SIMPLE HYPERPLASIA WITHOUT ATYPIA.**



#### SPECIMEN

Endometrial Curettings

#### GROSS

Received multiple grayish white tissue piece.

#### Microscopy

1. Section examined shows small and few cystically dilated endometrial glands with columnar lining with small round nucleus. Stroma shows mononuclear inflammatory cells.
2. No granuloma seen. No malignant cells seen.

**Note :** All biopsy specimen will be stored for 15 (fifteen) days, block and slides for 5 (five) years only from the time of receipt at the laboratory. No request, for any of the above, will be entertained after the due date.

#### Reference

- i) Rosai and Ackerman's Surgical Pathology.
- ii) Modern Surgical Pathology.

**Gulshan Yadav, MD**  
Consultant Pathologist