

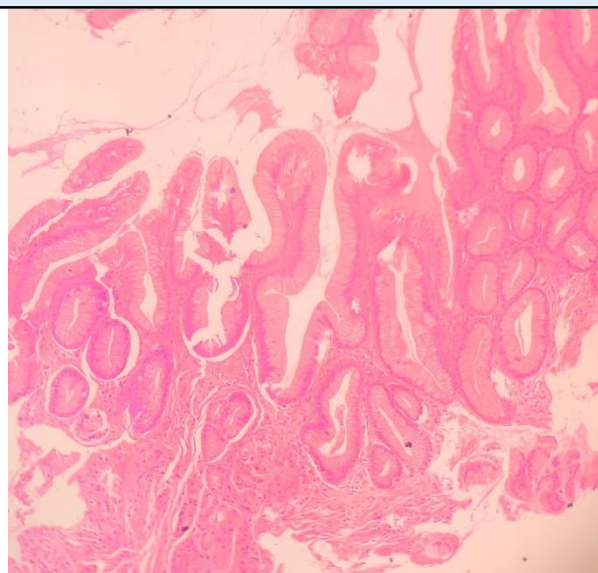
| | | | | | |
|---------------------|-----------------------|--------------------|----------------------------|--------------------------|-------------|
| Patient Name | Mr. RAM KISHAN | Client Name | Sunrise Diagnostic Centre, | Specimen Received | 10-Nov-2019 |
| Age/Sex | 73 Years/Male | | Agra | Specimen Type | Tissue |
| Patient ID | 011911100007 | | | Collection Date | 10-Nov-2019 |
| Specimen ID | MOLQ/B-2116/19 | | | Report Date | 15-Nov-2019 |

SURGICAL PATHOLOGY REPORT

Polypoidal Lesion at Lower Oesophagus-Gastric Junctions.

DIAGNOSIS

BENIGN LESION (INFLAMMATORY POLYP).



SPECIMEN

Polypoidal Lesion at Lower Oesophagus-Gastric Junctions.

GROSS

Received tiny greyish white tissue piece.

Microscopy

1. Section examined shows submucosal glands with columnar lining epithelium with small round to oval nucleus surrounded by fibrocollagenous tissue, blood vessels and few inflammatory cells.
2. No granuloma seen. No malignant cells seen in sample received.

Note : All biopsy specimen will be stored for 15 (fifteen)days, block and slides for 5(five) years only from the time of receipt at the laboratory. No request ,for any of the above ,will be entertained after the due date.

Reference

- i) Rosai and Ackerman's Surgical Pathology.
- ii) Modern Surgical Pathology.

Gulshan Yadav, MD
Consultant Pathologist