

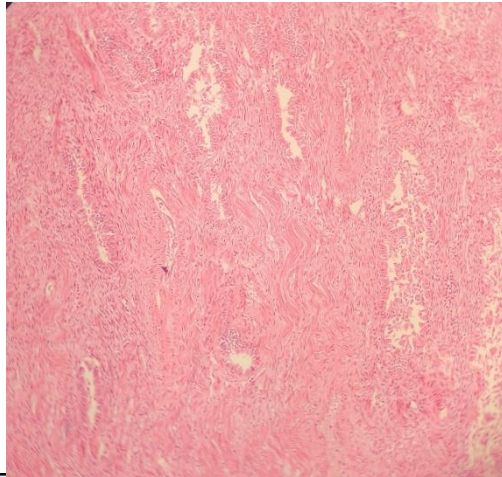
Patient Name	Mrs. PARBHA 42059	Client Name	Pushpanjali Hospital	Specimen Received	09-Nov-2019
Age/Sex	40 Years/Female		(Rewari)	Specimen Type	Tissue
Patient ID	011911090229			Collection Date	09-Nov-2019
Specimen ID	MOLQ/B-2115/19			Report Date	15-Nov-2019

SURGICAL PATHOLOGY REPORT

Uterus with Cervix with bilateral tubes

DIAGNOSIS

CHRONIC CERVICITIS WITH ENDOMETRIAL POLYP.



SPECIMEN

Uterus with Cervix with bilateral tubes

GROSS

Received 8x6.5 cm uterus with cervix with bilateral tubes. Cut section shows 3.7x1.8 cm endometrial polyp.

Microscopy

Section examined shows

- 1) Endometrium with proliferative phase
- 2) Myometrium with muscle bundles
- 3) Cervix with mononuclear inflammatory cells
- 4) Bilateral tubes unremarkable
- 5) Polyp with endometrial glands and stromal cells

Note : All biopsy specimen will be stored for 15 (fifteen) days, block and slides for 5 (five) years only from the time of receipt at the laboratory. No request, for any of the above, will be entertained after the due date.

Reference

- i) Rosai and Ackerman's Surgical Pathology.
- ii) Modern Surgical Pathology.

A handwritten signature in black ink, appearing to read 'Gulshan', written over a light blue rectangular background.

Gulshan Yadav, MD
Consultant Pathologist