

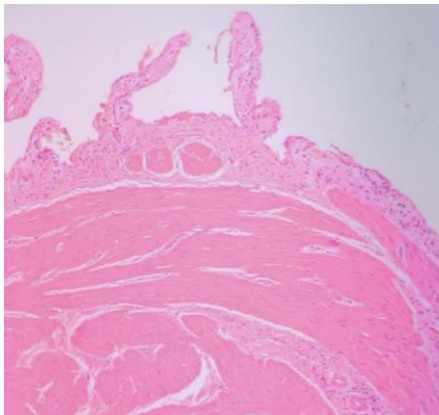
Patient Name	Mrs. KAVITA	Client Name	Civil Hospital Sec-10	Specimen Received	09/11/19
Age/Sex	32YRS/F			Specimen Type	Tissue
Patient ID	011911090132			Collection Date	09/11/19
Specimen ID	MOLQ/B-2114/19			Report Date	15/11/19

SURGICAL PATHOLOGY REPORT

Gall Bladder

DIAGNOSIS

CHOLECYSTITIS AND CHOLELITHIASIS.



SPECIMEN

Gall Bladder

GROSS

Received 10x2.8 cm long gall bladder. Cut section shows tiny stones. Wall thickness 0.2 mm.


Microscopy

1. Section examined shows ulcerative mucosa and Rokitansky-Aschoff sinus (irregularly shaped tubular structures lined by cuboidal lining epithelium with round to oval nucleus) with fibro collagenous tissue and inflammatory cells (lymphocytes).

Note : All biopsy specimen will be stored for 15 (fifteen) days, block and slides for 5 (five) years only from the time of receipt at the laboratory. No request, for any of the above, will be entertained after the due date.

Reference

- i) Rosai and Ackerman's Surgical Pathology.
- ii) Modern Surgical Pathology.


Gulshan Yadav, MD
Consultant Pathologist