

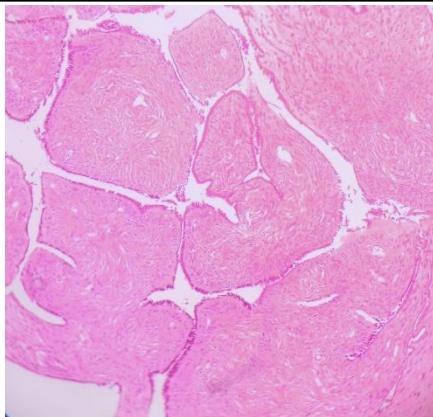
<b>Patient Name</b>	Ms. SONIYA	<b>Client Name</b>	Vedic Hospital	<b>Specimen Received</b>	09/11/19
<b>Age/Sex</b>	25YRS/F			<b>Specimen Type</b>	Tissue
<b>Patient ID</b>	011911090126			<b>Collection Date</b>	09/11/19
<b>Specimen ID</b>	MOLQ/B-2113/19			<b>Report Date</b>	15/11/19

## SURGICAL PATHOLOGY REPORT

### Right Ovarian Cyst with Hemorrhage and Torsion

#### DIAGNOSIS

**BENIGN CYSTADENOMA WITH HEMORRHAGIC CYST (RIGHT OVARY).**



#### **SPECIMEN**

Right Ovarian Cyst with Hemorrhage and Torsion

#### **GROSS**

Received two grayish white tissue piece measuring 7x6 cm and 8.5x3 cm, already cut open with blood clot and tube.

#### **Microscopy**

- Section examined shows cuboidal lining epithelium with round to oval nucleus and flat interphase. Deeper tissue shows fibrocollagenous tissue, blood vessels and RBCs. No granuloma seen. No malignant cells seen.
- Tube is unremarkable.

**Note :** All biopsy specimen will be stored for 15 (fifteen)days, block and slides for 5(five) years only from the time of receipt at the laboratory. No request ,for any of the above ,will be entertained after the due date.

#### **Reference**

- Rosai and Ackerman's Surgical Pathology.
- Modern Surgical Pathology.

**Gulshan Yadav, MD**  
Consultant Pathologist