

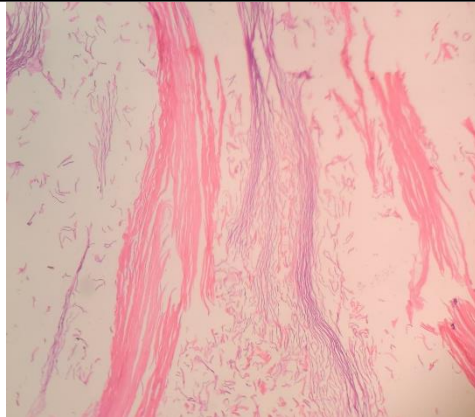
Patient Name	Ms. RAM BATI	Client Name	Walk-in	Specimen Received	09/11/19
Age/Sex	55YRS/F			Specimen Type	Tissue
Patient ID	011911090057			Collection Date	06/11/19
Specimen ID	MOLQ/B-2112/19			Report Date	15/11/19

SURGICAL PATHOLOGY REPORT

Mass near Postero-Lateral aspect of Abdomen

DIAGNOSIS

BENIGN EPIDERMAL CYST.



SPECIMEN

Mass near Postero-Lateral aspect of Abdomen

GROSS

Received multiple grayish white tissue piece.

Microscopy

1. Section examined shows abundant keratin flakes with fibrocollagenous tissue.
2. No granuloma seen. No malignant cells seen.

Note : All biopsy specimen will be stored for 15 (fifteen) days, block and slides for 5 (five) years only from the time of receipt at the laboratory. No request, for any of the above, will be entertained after the due date.

Reference

- i) Rosai and Ackerman's Surgical Pathology.
- ii) Modern Surgical Pathology.

Gulshan Yadav, MD
Consultant Pathologist