

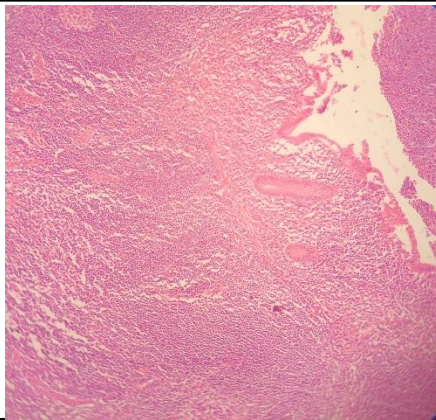
Patient Name	Mrs. NAJRANA	Client Name	Unique Lab, Tauru	Specimen Received	06/11/19
Age/Sex	23 YRS/F			Specimen Type	Tissue
Patient ID	011911060120			Collection Date	06/11/19
Specimen ID	MOLQ/B-2095/19			Report Date	13/11/19

SURGICAL PATHOLOGY REPORT

Appendix

DIAGNOSIS

ACUTE APPENDICITIS



SPECIMEN

Appendix

GROSS

Received 4.1x2 cm long appendix. Cut section shows feco-lith.

Microscopy

1. Section examined shows lymphoid follicles with ulcerative mucosa. Deeper tissue shows inflammatory cells (polymorphs and lymphocytes).
2. No granuloma seen.
3. No malignant cells seen.

Note : All biopsy specimen will be stored for 15 (fifteen)days, block and slides for 5(five) years only from the time of receipt at the laboratory. No request ,for any of the above ,will be entertained after the due date.

Reference

- i) Rosai and Ackerman's Surgical Pathology.
- ii) Modern Surgical Pathology.



Gulshan Yadav, MD
Consultant Pathologist