

Patient Name	Mr. Vishnu Raj Atreya	Client Name	Home Collection	Specimen Received	08-Nov-19
Age/Sex	77 Years/Male			Specimen Type	Tissue
Patient ID	011911080209	Ref. Doctor	Dr. Archit Pandit	Collection Date	08-Nov-19
Specimen ID	MolQ-IHC-43112019			Report Date	12-Nov-19

SURGICAL PATHOLOGY REPORT

Peritoneal Nodule (Carcinoma Gall Bladder)

DIAGNOSIS

Estrogen Receptor α - Negative
Progesterone Receptor- Negative
Her-2/neu- Negative

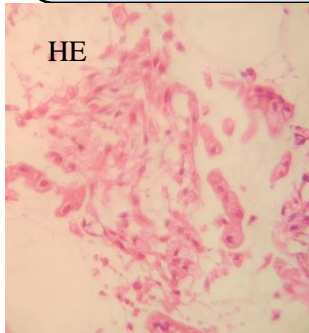


Fig. 1

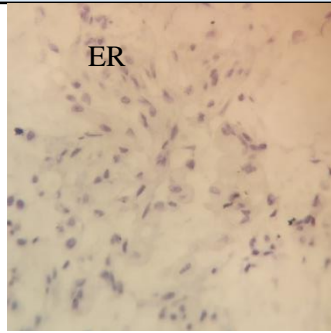


Fig. 2

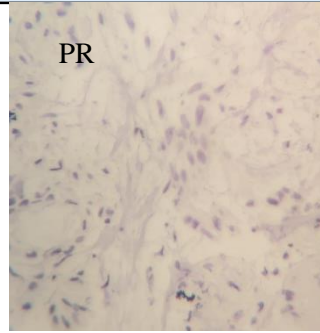


Fig. 3

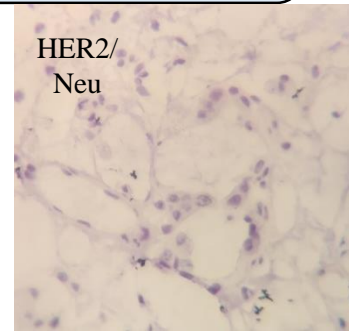


Fig. 4

SPECIMEN

Peritoneal Nodule

GROSS

Received one FFPE labeled with SB 4353/19

Microscopy

Estrogen Receptor α (ER)

-% Cells immunoreactive – 00%

Intensity- Score 0

Internal control-Positive

Interpretation-Negative

Allred Score: 00/08

Progesterone Receptor (PR)

-% Cells immunoreactive – 00%

Intensity- Score 0

Internal control-Positive

Interpretation-Negative

Allred Score: 00/08

Her-2/neu

-% Cells immunoreactive – 00%

Intensity- Score 0

Internal control-Positive

Interpretation-Negative

Note : All biopsy specimen will be stored for 15 (fifteen)days, block and slides for 5(five) years only from the time of receipt at the laboratory. No request ,for any of the above ,will be entertained after the due date.

Reference

- i) Rosai and Ackerman's Surgical Pathology.
- ii) Modern Surgical Pathology.

Gulshan Yadav, MD
Consultant Pathologist