

Human Epidermal Growth Factor Receptor 2 Immunohistochemistry

Test Description

Test is useful for determining overexpression of HER2 protein of gastric and esophageal adenocarcinoma in formalin-fixed, paraffin-embedded tissue sections (with reflex to FISH testing).

Clinical Information

Human epidermal growth factor receptor 2 (*HER2*), is a proto-oncogene located on chromosome 17q21 that encodes a transmembrane protein with tyrosine kinase activity, a member of the HER receptor family and is involved in signal transduction pathways, leading to cell growth and differentiation. Amplification and overexpression of the *HER2* gene have been associated with a shorter disease-free survival and shorter overall survival in gastric and gastroesophageal junction cancers, as well as breast, endometrial, and ovarian cancer.

Specimen

Sample Type: FFPE Block SB 2598/18
Site: Rectum Hemicolectomy
Pathology ID: MOLQ/IHC-41112019
Disease: Metastatic Carcinoma Colon

Scoring

The scoring system is based on type and origin of tumor.

Score	Staining Pattern	Interpretation
0	No staining or <10% of cells	Negative
1+	Faint incomplete staining of cell membrane in >10% of Tumor cells.	Negative
2+	Weak to moderate complete staining of cell membrane >10% of Tumor cells.	Weak Positive/ Equivocal
3+	Strong complete staining of cell membrane in >10% of Tumor cells.	Strong Positive

Interpretation

Results are reported as positive (3+ HER2 protein expression), equivocal (2+), or negative (0 or 1+).

Equivocal (2+) cases will automatically reflex to FISH testing at an additional charge.

Methodology

Immunostaining for HER2 protein was done using PathnSitu Rabbit Anti-Human HER2 monoclonal (Clone EP3) antibody (#PR047)

References

- Rosai and Ackerman's Surgical Pathology.
- NCCN Guidelines Journal of the National Comprehensive Cancer Network 2006 4
- Ruschoff J, Dietel M, Baretton G, et al. HER2 diagnostics in gastric cancer guideline validation and development of standardized immunohistochemical testing. *Virchows Arch. Sep; 457 (3):299-307*
- Brandon S *et al.* HER2/neu Testing in Gastric Cancer by Immunohistochemistry. *Arch Pathol Lab Med* 2014 138
- Ramin Azarhoosh *et al.* HER2/neu gene amplification in gastric adenocarcinoma and its relationship with clinical and pathological findings. *J Gastrointest Oncol.* 2017 8:6

Clinician

Clinician Name: Dr. Amit Verma
 Medical Facility: Max Hospital.
 Pathologist: Not Provided

**Human Epidermal Growth Factor Receptor 2
(HER2/neu): Negative (Score 0)**

Microscopy Evaluation

HE Staining (Figure 1)

Tumor cells: 85%

Her2/neu by IHC: Negative (Score 0)

Percentage of cells with uniform membrane staining: 00% (Figure 2)

HE Stained Section

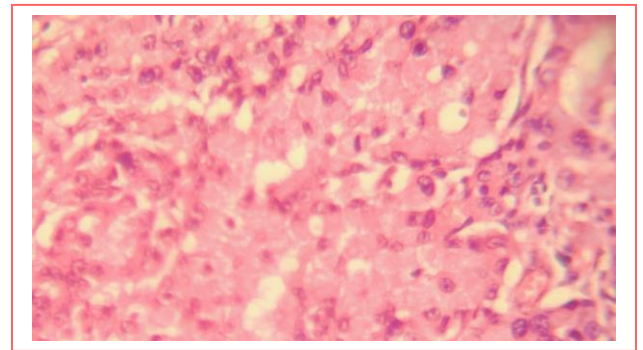


Figure 1

HER2/Neu IHC- Tumor

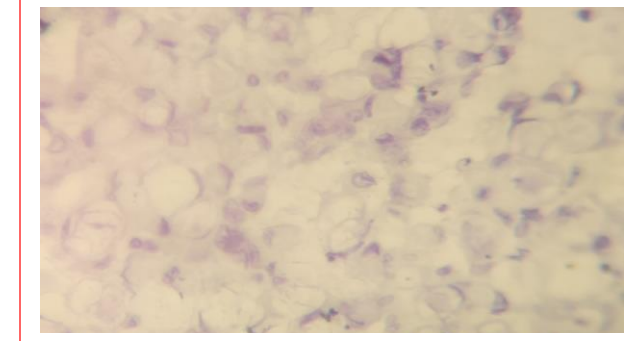


Figure 2

Reviewed By



Dr. Gulshan Yadav, MD
 Head, Pathology