

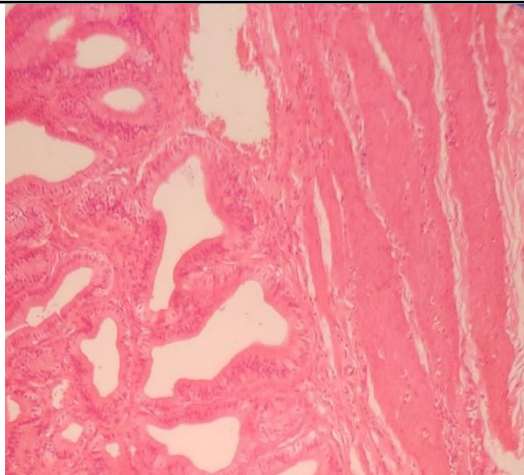
Patient Name	Mr. RAMNARESH	Client Name	Sunrise Diagnostic Centre,	Specimen Received	05-Nov-19
Age/Sex	50Years/Male		Agra	Specimen Type	Tissue
Patient ID	011911050008			Collection Date	05-Nov-19
Specimen ID	MOLQ/B-2089/19			Report Date	12-Nov-19

SURGICAL PATHOLOGY REPORT

Gall Bladder

DIAGNOSIS

CHOLECYSTITIS AND CHOLELITHIASIS.



SPECIMEN

Gall Bladder

GROSS

Received 6.8x2.9 cm long gall bladder already cut open with stones.

Microscopy

1. Section examined shows ulcerative mucosa and Rokitansky-Aschoff sinuses (irregularly shaped tubular structures lined by cuboidal lining epithelium with round to oval nucleus) with fibro collagenous tissue and inflammatory cells (lymphocytes).

Note : All biopsy specimen will be stored for 15 (fifteen) days, block and slides for 5 (five) years only from the time of receipt at the laboratory. No request, for any of the above, will be entertained after the due date.

Reference

- i) Rosai and Ackerman's Surgical Pathology.
- ii) Modern Surgical Pathology.

Guishan Yadav, MD
Consultant Pathologist