

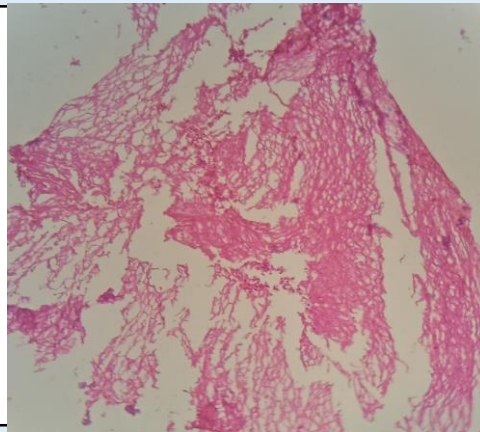
<b>Patient Name</b>	Mrs. PARMESHWARI	<b>Client Name</b>	Tilak Hospital	<b>Specimen Received</b>	04/11/19
<b>Age/Sex</b>	47 YRS/F			<b>Specimen Type</b>	Tissue
<b>Patient ID</b>	011911040253			<b>Collection Date</b>	04/11/19
<b>Specimen ID</b>	MOLQ/B-2082/19			<b>Report Date</b>	08/11/19

## SURGICAL PATHOLOGY REPORT

### Inflamed cyst in scapula region

#### DIAGNOSIS

**Infected Cystic lesion.**



#### **SPECIMEN**

Inflamed cyst in scapula region

#### **GROSS**

Received multiple grayish white tissue piece, 3x4 cm in aggregate.


#### **Microscopy**

Section examined shows keratin flakes with inflammatory cells (polymorphs, lymphocytes) and RBCs. No granuloma and no malignant cells seen.

**Note :** All biopsy specimen will be stored for 15 (fifteen) days, block and slides for 5 (five) years only from the time of receipt at the laboratory. No request, for any of the above, will be entertained after the due date.

#### **Reference**

- i) Rosai and Ackerman's Surgical Pathology.
- ii) Modern Surgical Pathology.

  
**Gulshan Yadav, MD**  
**Consultant Pathologist**