

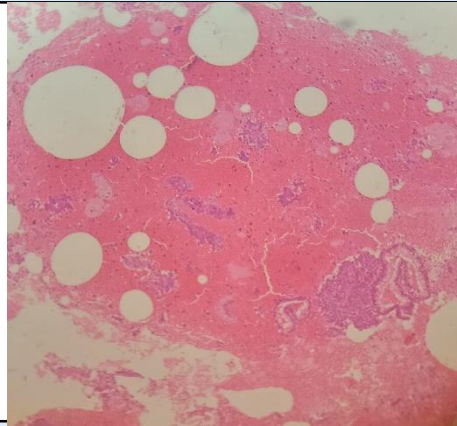
<b>Patient Name</b>	Mrs. REKHA	<b>Client Name</b>	Asian Diagnostic Centre	<b>Specimen Received</b>	04/11/19
<b>Age/Sex</b>	35 YRS/F			<b>Specimen Type</b>	Tissue
<b>Patient ID</b>	011911040222			<b>Collection Date</b>	04/11/19
<b>Specimen ID</b>	MOLQ/B-2080/19			<b>Report Date</b>	08/11/19

## SURGICAL PATHOLOGY REPORT

### Endometrium

#### DIAGNOSIS

**Simple Hyperplasia Without Atypia.**



#### SPECIMEN

Endometrium

#### GROSS

Received multiple grayish white tissue piece.

#### Microscopy


Section examined shows small and occasional cystically dilated endometrial glands with columnar lining epithelium and round to oval nucleus. Stroma shows mononuclear inflammatory cells.

No granuloma and no malignant cells seen.

**Note :** All biopsy specimen will be stored for 15 (fifteen)days, block and slides for 5(five) years only from the time of receipt at the laboratory. No request ,for any of the above ,will be entertained after the due date.

#### Reference

- i) Rosai and Ackerman's Surgical Pathology.
- ii) Modern Surgical Pathology.

  
**Gulshan Yadav, MD**  
Consultant Pathologist