

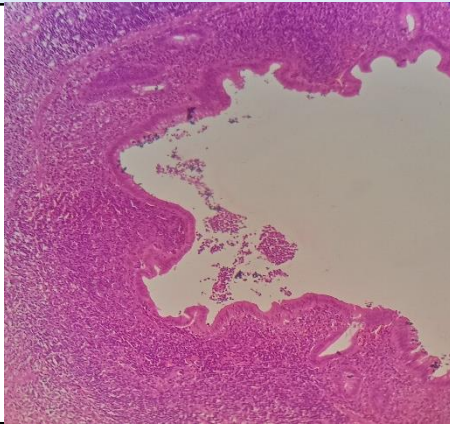
Patient Name	Mr. VIKASH	Client Name	Goyal Nursing Home	Specimen Received	03/11/19
Age/Sex	24 YRS/M	(Palwal)		Specimen Type	Tissue
Patient ID	011911030199			Collection Date	03/11/19
Specimen ID	MOLQ/B-2077/19			Report Date	08/11/19

SURGICAL PATHOLOGY REPORT

Appendix

DIAGNOSIS

ACUTE ON CHRONIC APPENDICITIS



SPECIMEN

Appendix

GROSS

Received 4.3x1.2 cm long appendix. Cut section shows feco-lith.

Microscopy

Section examined shows lymphoid follicles with ulcerative mucosa. Deeper tissue shows inflammatory cells (polymorphs and lymphocytes) and multinucleated giant cells. No granuloma seen. No malignant cells seen.

Note : All biopsy specimen will be stored for 15 (fifteen)days, block and slides for 5(five) years only from the time of receipt at the laboratory. No request ,for any of the above ,will be entertained after the due date.

Reference

- i) Rosai and Ackerman's Surgical Pathology.
- ii) Modern Surgical Pathology.

Gulshan Yadav, MD
Consultant Pathologist