

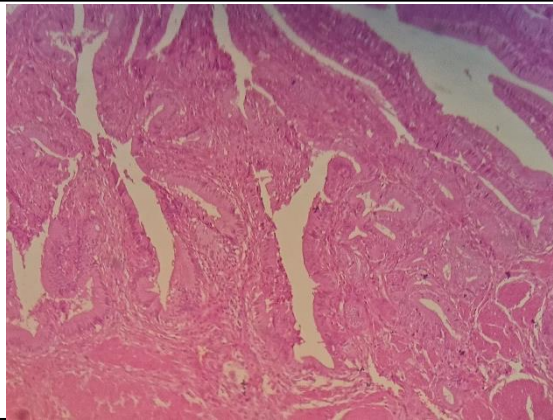
Patient Name	Mr. RAMESH CHAND	Client Name	Goyal Nursing Home	Specimen Received	03/11/19
Age/Sex	39 YRS/M	(Palwal)		Specimen Type	Tissue
Patient ID	011911030198			Collection Date	03/11/19
Specimen ID	MOLQ/B-2078/19			Report Date	08/11/19

SURGICAL PATHOLOGY REPORT

Gall Bladder

DIAGNOSIS

CHOLECYSTITIS AND CHOLELITHIASIS.



SPECIMEN

Gall Bladder

GROSS

Received 8x3 cm long gall bladder already cut open with another container containing multiple stones.

Microscopy

Section examined shows ulcerative mucosa and Rokitansky Aschoff sinus (irregularly shaped tubular structures lined by cuboidal lining epithelium with round to oval nucleus) with fibro collagenous tissue and inflammatory cells (lymphocytes). No granuloma and no malignant cells seen.

Note : All biopsy specimen will be stored for 15 (fifteen) days, block and slides for 5 (five) years only from the time of receipt at the laboratory. No request, for any of the above, will be entertained after the due date.

Reference

- i) Rosai and Ackerman's Surgical Pathology.
- ii) Modern Surgical Pathology.



Gulshan Yadav, MD
Consultant Pathologist