

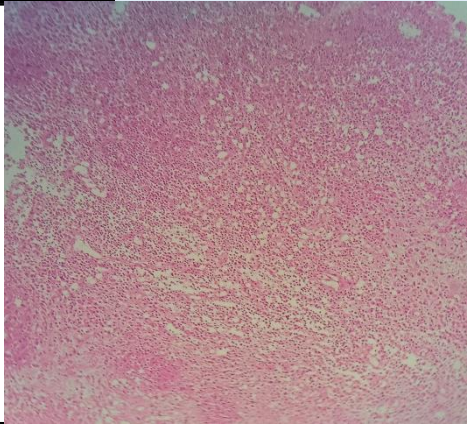
Patient Name	Mr. RAM NIWAS KUMAR	Client Name	Polaris Hospital	Specimen Received	03/11/19
Age/Sex	23 YRS/M			Specimen Type	Tissue
Patient ID	011911030053			Collection Date	03/11/19
Specimen ID	MOLQ/B-2075/19			Report Date	08/11/19

SURGICAL PATHOLOGY REPORT

Small synovial tissue for left shoulder.

DIAGNOSIS

Granulomatous reaction
(Tubercular Pathology Suspicious)



SPECIMEN

Small synovial tissue for left shoulder.

GROSS

Received multiple grayish white tissue piece.


Microscopy

Section examined shows epithelioid cells granuloma with lymphocytes, epithelioid cells, necrosis and multinucleated giant cells. No malignant cells seen.

Note : All biopsy specimen will be stored for 15 (fifteen)days, block and slides for 5(five) years only from the time of receipt at the laboratory. No request ,for any of the above ,will be entertained after the due date.

Reference

- i) Rosai and Ackerman's Surgical Pathology.
- ii) Modern Surgical Pathology.


Gulshan Yadav, MD
Consultant Pathologist