

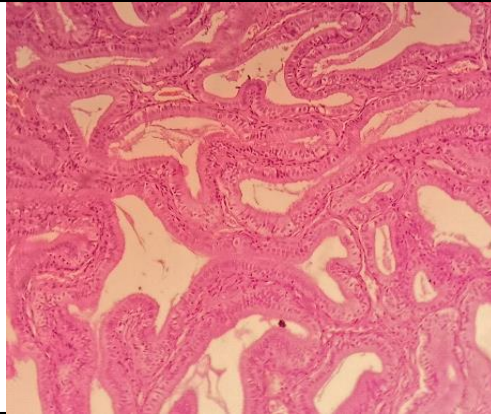
<b>Patient Name</b>	Mrs. RAMSHRE	<b>Client Name</b>	Goyal Nursing Home	<b>Specimen Received</b>	02/11/19
<b>Age/Sex</b>	50 YRS/F	(Palwal)		<b>Specimen Type</b>	Tissue
<b>\Patient ID</b>	011911020276			<b>Collection Date</b>	02/11/19
<b>Specimen ID</b>	MOLQ/B-2068/19			<b>Report Date</b>	07/11/19

## SURGICAL PATHOLOGY REPORT

### Gall Bladder

#### DIAGNOSIS

#### CHOLECYSTITIS AND CHOLELITHIASIS.



#### SPECIMEN

Gall Bladder

#### GROSS

Received 6.5x2.9 cm long gall bladder with stones wall thickness 0.3mm.

#### Microscopy

Section examined shows ulcerative mucosa and Rokitansky-Aschoff sinuses (irregularly shaped tubular structures lined by cuboidal lining epithelium with round to oval nucleus) with fibro collagenous tissue and inflammatory cells (lymphocytes).

**Note :** All biopsy specimen will be stored for 15 (fifteen) days, block and slides for 5 (five) years only from the time of receipt at the laboratory. No request, for any of the above, will be entertained after the due date.

#### Reference

- i) Rosai and Ackerman's Surgical Pathology.
- ii) Modern Surgical Pathology.

**Gulshan Yadav, MD**  
Consultant Pathologist