

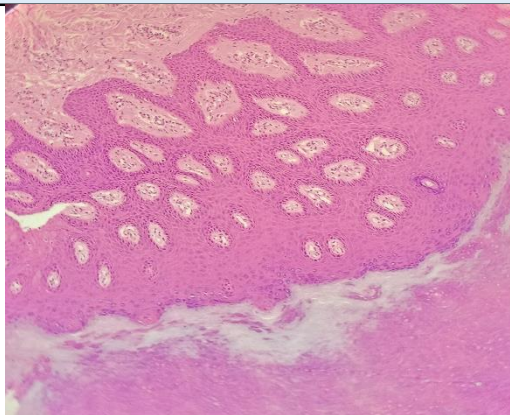
<b>Patient Name</b>	Mr. ROHAN NANDAL	<b>Client Name</b>	Safe Hands Diagnostic,	<b>Specimen Received</b>	02/11/19
<b>Age/Sex</b>	24 YRS/M		Gurgaon	<b>Specimen Type</b>	Tissue
<b>Patient ID</b>	011911020061			<b>Collection Date</b>	02/11/19
<b>Specimen ID</b>	MOLQ/B-2065/19			<b>Report Date</b>	07/11/19

## SURGICAL PATHOLOGY REPORT

### Left hand index finger

#### DIAGNOSIS

**Benign Hyperkeratotic Lesion.**



#### SPECIMEN

Left hand index finger

#### GROSS

Received two grayish white tissue piece measuring 1.2x1.8 cm in aggregate.

#### Microscopy

Section examined shows hyperplastic squamous lining epithelium with keratosis and parakeratosis. Stroma shows glands, fibro collagenous tissue. No granuloma and no malignant cells.

**Note :** All biopsy specimen will be stored for 15 (fifteen) days, block and slides for 5 (five) years only from the time of receipt at the laboratory. No request, for any of the above, will be entertained after the due date.

#### Reference

- i) Rosai and Ackerman's Surgical Pathology.
- ii) Modern Surgical Pathology.

**Gulshan Yadav, MD**  
Consultant Pathologist