

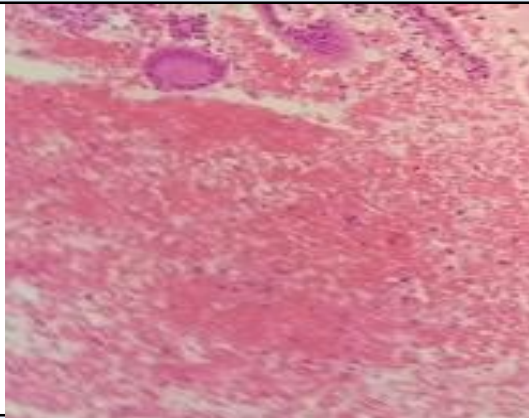
Patient Name	Mrs. KAMLESH	Client Name	Pushpanjali Hospital	Specimen Received	01/11/19
Age/Sex	45 YRS/F	(Rewari)		Specimen Type	Tissue
Patient ID	011911010300			Collection Date	01/11/19
Specimen ID	MOLQ/B-2062/19			Report Date	07/11/19

SURGICAL PATHOLOGY REPORT

Endometrial biopsy

DIAGNOSIS

Kindly Co-relate Clinically



SPECIMEN

Endometrial biopsy

GROSS

Received multiple grayish white tissue piece.

Microscopy

Section examined shows few broken endometrial glands with cuboidal lining epithelium having round to oval nucleus stroma shows mononuclear inflammatory cells and RBCs. No granuloma and no malignant cells seen.

Note : All biopsy specimen will be stored for 15 (fifteen) days, block and slides for 5 (five) years only from the time of receipt at the laboratory. No request, for any of the above, will be entertained after the due date.

Reference

- i) Rosai and Ackerman's Surgical Pathology.
- ii) Modern Surgical Pathology.



Gulshan Yadav, MD
Consultant Pathologist