

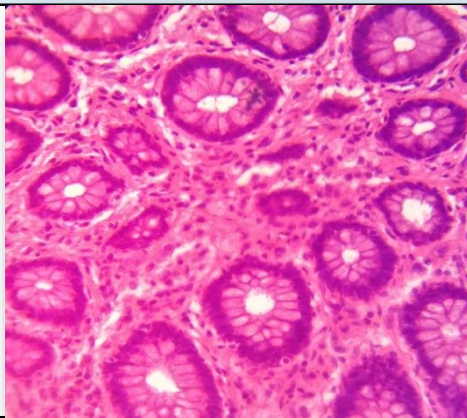
<b>Patient Name</b>	Mrs. SUNIL DEVI	<b>Client Name</b>	Pushpanjali Hospital	<b>Specimen Received</b>	31/10/19
<b>Age/Sex</b>	35 YRS/F	(Rewari)		<b>Specimen Type</b>	Tissue
<b>Patient ID</b>	011910310261			<b>Collection Date</b>	31/10/19
<b>Specimen ID</b>	MOLQ/B-2051/19(2)			<b>Report Date</b>	05/11/19

## SURGICAL PATHOLOGY REPORT

### Intestinal Hemorrhoid

#### DIAGNOSIS

#### Hemorrhoid



#### **SPECIMEN**

Intestinal Hemorrhoid

#### **GROSS**

Received two grayish white tissue piece measuring 1x1,2x2cm.

#### **Microscopy**

Section examined shows squamous lining epithelium with submucosal glands and large number of blood vessels. No granuloma and no malignant cells seen.

**Note :** All biopsy specimen will be stored for 15 (fifteen)days, block and slides for 5(five) years only from the time of receipt at the laboratory. No request ,for any of the above ,will be entertained after the due date.

#### **Reference**

- i) Rosai and Ackerman's Surgical Pathology.
- ii) Modern Surgical Pathology.

**Gulshan Yadav, MD**  
Consultant Pathologist