

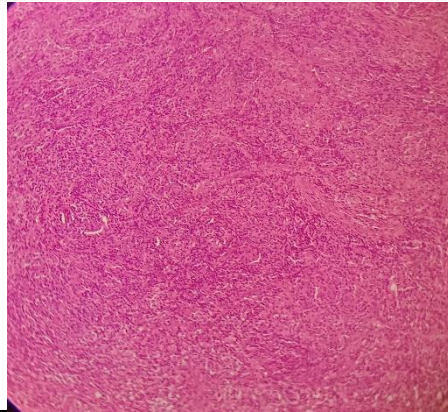
Patient Name	Mrs. SUNIL DEVI	Client Name	Pushpanjali Hospital	Specimen Received	31/10/19
Age/Sex	35 YRS/F	(Rewari)		Specimen Type	Tissue
Patient ID	011910310260			Collection Date	31/10/19
Specimen ID	MOLQ/B-2051/19(1)			Report Date	05/11/19

SURGICAL PATHOLOGY REPORT

Growth in anal canal

DIAGNOSIS

Inflammatory Lesion.



SPECIMEN

Growth in anal canal

GROSS

Received multiple grayish white tissue piece measuring 1x1cm in aggregate.

Microscopy

Section examined shows squamous lining epithelium with mucosal lining epithelium having columnar cells small round nucleus with submucosal glands. Section also shows heavy inflammatory cells (Polymorphs, Lymphocytes, Eosinophil and Histiocytes). No granuloma and no malignant cells seen.

Note : All biopsy specimen will be stored for 15 (fifteen)days, block and slides for 5(five) years only from the time of receipt at the laboratory. No request ,for any of the above ,will be entertained after the due date.

Reference

- i) Rosai and Ackerman's Surgical Pathology.
- ii) Modern Surgical Pathology.

Gulshan Yadav, MD
Consultant Pathologist