

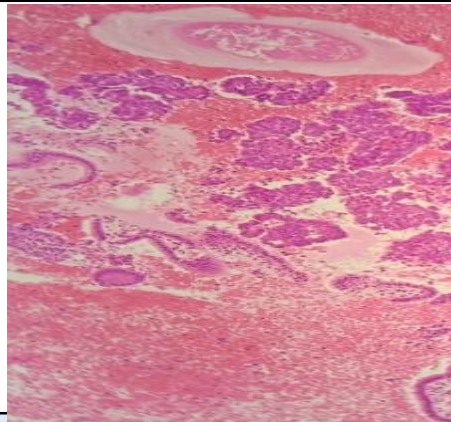
<b>Patient Name</b>	Mrs. SHANTI DEVI	<b>Client Name</b>	Pushpanjali Hospital	<b>Specimen Received</b>	31/10/19
<b>Age/Sex</b>	77 YRS/F	(Rewari)		<b>Specimen Type</b>	Tissue
<b>Patient ID</b>	011910310259			<b>Collection Date</b>	31/10/19
<b>Specimen ID</b>	MOLQ/B-2050/19			<b>Report Date</b>	05/11/19

## SURGICAL PATHOLOGY REPORT

### Endometrial biopsy

#### DIAGNOSIS

Kindly Co-relate Clinically



#### SPECIMEN

Endometrial biopsy

#### GROSS

Received multiple grayish white tissue piece.


#### Microscopy

Paucicellular section examined shows occasional broken endometrial glands with cuboidal lining epithelium small round nucleus, fibrin, RBCs and stromal cells. No granuloma and no malignant cells seen.

**Note :** All biopsy specimen will be stored for 15 (fifteen)days, block and slides for 5(five) years only from the time of receipt at the laboratory. No request ,for any of the above ,will be entertained after the due date.

#### Reference

- i) Rosai and Ackerman's Surgical Pathology.
- ii) Modern Surgical Pathology.

  
**Gulshan Yadav, MD**  
Consultant Pathologist