

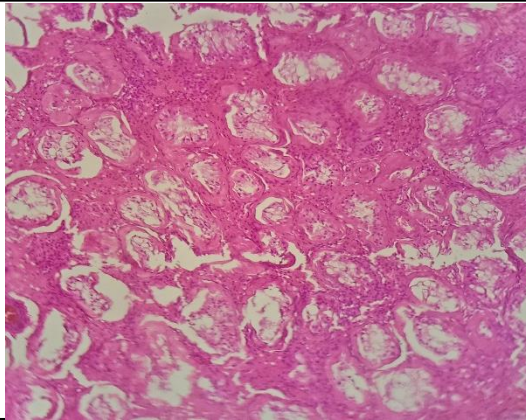
Patient Name	Mr. NARENDER 39585	Client Name	Pushpanjali Hospital	Specimen Received	31/10/19
Age/Sex	29 YRS/M	(Rewari)		Specimen Type	Tissue
Patient ID	011910310258			Collection Date	31/10/19
Specimen ID	MOLQ/B-2049/19			Report Date	05/11/19

SURGICAL PATHOLOGY REPORT

Right testis

DIAGNOSIS

Atrophic testis



SPECIMEN

Right testis

GROSS

Received 3x2.0 cm grayish white tissue piece with epididymis.

Microscopy

Section examined shows seminiferous tubules with few immature spermatogenic cells thick basement membrane and supporting cells. No granuloma and no malignant cells.

Note : All biopsy specimen will be stored for 15 (fifteen)days, block and slides for 5(five) years only from the time of receipt at the laboratory. No request ,for any of the above ,will be entertained after the due date.

Reference

- i) Rosai and Ackerman's Surgical Pathology.
- ii) Modern Surgical Pathology.

Gulshan Yadav, MD
Consultant Pathologist