

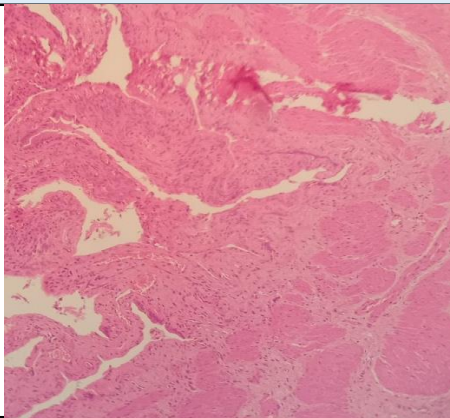
Patient Name	Mrs. REETA DEVI	Client Name	Polaris Hospital	Specimen Received	31/10/19
Age/Sex	38 YRS/F			Specimen Type	Tissue
Patient ID	011910310137			Collection Date	31/10/19
Specimen ID	MOLQ/B-2046/19			Report Date	05/11/19

SURGICAL PATHOLOGY REPORT

Left (Dermoid cyst)

DIAGNOSIS

Dermoid Cyst



SPECIMEN

Left (Dermoid cyst)

GROSS

Received 4x3 cm grayish white tissue piece with hairs.

Microscopy

Section examined shows squamous epithelial cells fibro collagenous tissue blood vessels, hairs. No granuloma and no malignant cells seen and tube unremarkable.

Note : All biopsy specimen will be stored for 15 (fifteen)days, block and slides for 5(five) years only from the time of receipt at the laboratory. No request ,for any of the above ,will be entertained after the due date.

Reference

- i) Rosai and Ackerman's Surgical Pathology.
- ii) Modern Surgical Pathology.

Gulshan Yadav, MD
Consultant Pathologist