

Patient Name	Ms. Deep M Singh	Client Name	Home Collection	Specimen Received	24-Oct-19
Age/Sex	60 Years/Female			Specimen Type	Tissue
Patient ID	011910240089			Collection Date	24-Oct-19
Specimen ID	MolQ-IHC-39102019			Report Date	04-Nov-19

SURGICAL PATHOLOGY REPORT

Endometrium

DIAGNOSIS

Estrogen Receptor α - Positive
Progesterone Receptor- Positive
Her-2/neu- Negative

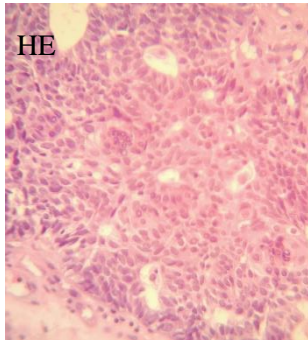


Fig. 1

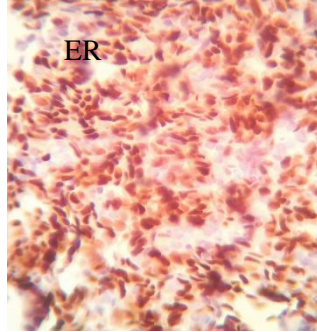


Fig. 2

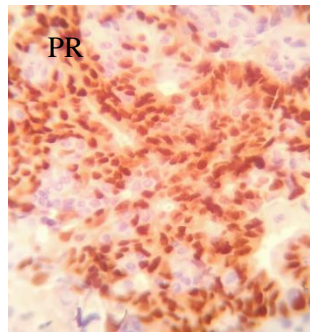


Fig. 3

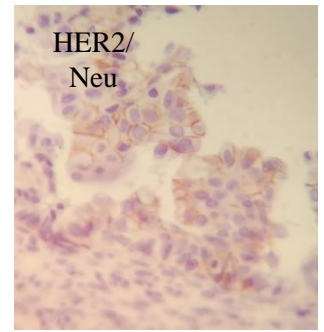


Fig. 4

SPECIMEN

Endometrium

Microscopy

Estrogen Receptor α (ER)

-% Cells immunoreactive – 80%

Intensity- +++ (Score 3)

Internal control-Positive

Interpretation-Positive

Allred Score: 08/08

Progesterone Receptor (PR)

-% Cells immunoreactive – 80%

Intensity- +++ (Score 3)

Internal control-Positive

Interpretation-Positive

Allred Score: 08/08

Her-2/neu

-% Cells immunoreactive – 08%

Intensity- + (Score 0)

(Little Staining in <10% of cells)

Internal control-Positive

Interpretation-Negative

Note : All biopsy specimen will be stored for 15 (fifteen)days, block and slides for 5(five) years only from the time of receipt at the laboratory. No request ,for any of the above ,will be entertained after the due date.

Reference

- i) Rosai and Ackerman's Surgical Pathology.
- ii) Modern Surgical Pathology.

GROSS

Received one FFPE labeled with H 2380/19

Gulshan Yadav, MD
Consultant Pathologist