

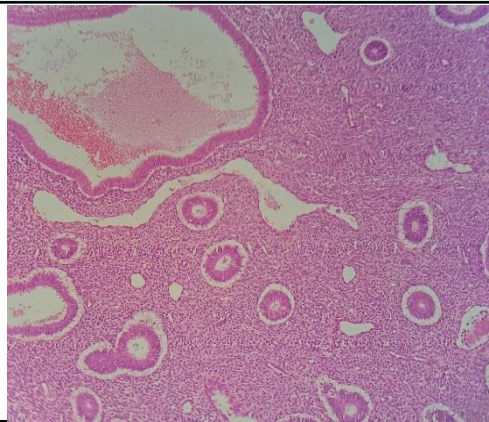
<b>Patient Name</b>	Ms. PINKI	<b>Client Name</b>	Delhi Hospital & Maternity	<b>Specimen Received</b>	30/10/19
<b>Age/Sex</b>	32 YRS/F	Home		<b>Specimen Type</b>	Tissue
<b>Patient ID</b>	011910300003			<b>Collection Date</b>	30/10/19
<b>Specimen ID</b>	MOLQ/B-2037/19(2)			<b>Report Date</b>	04/11/19

## SURGICAL PATHOLOGY REPORT

### Endometrium

#### DIAGNOSIS

**Disordered Proliferative Phase and Hyper progesteronic Effect.**



#### SPECIMEN

Endometrium

#### GROSS

Received multiple grayish white tissue piece.

#### Microscopy

Section examined shows small, tortuous and broken endometrial glands with columnar lining epithelium and small round to oval nucleus. Stroma shows mononuclear inflammatory cells and decidual cells.

**Note :** All biopsy specimen will be stored for 15 (fifteen)days, block and slides for 5(five) years only from the time of receipt at the laboratory. No request ,for any of the above ,will be entertained after the due date.

#### Reference

- i) Rosai and Ackerman's Surgical Pathology.
- ii) Modern Surgical Pathology.

**Gulshan Yadav, MD**  
Consultant Pathologist