

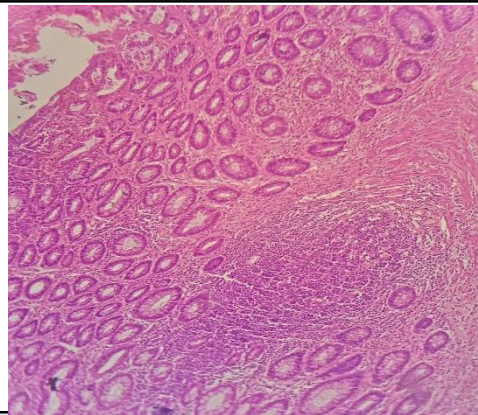
Patient Name	Mr. PARVEEN	Client Name	Chiranjeev Path Lab	Specimen Received	29-10-2019
Age/Sex	36 YRS/M			Specimen Type	Tissue
Patient ID	011910290059			Collection Date	29-10-2019
Specimen ID	MOLQ/B-2035/19			Report Date	31-10-2019

SURGICAL PATHOLOGY REPORT

Hemorrhoids

DIAGNOSIS

Hemorrhoids



SPECIMEN

Hemorrhoids

GROSS

Received 6x2.1 cm greyish white tissue piece.

Microscopy

Section examined shows submucosal glands, fibro collagenous tissue with blood vessels. No granuloma and no malignant cells seen.

Note : All biopsy specimen will be stored for 15 (fifteen)days, block and slides for 5(five) years only from the time of receipt at the laboratory. No request ,for any of the above ,will be entertained after the due date.

Reference

- i) Rosai and Ackerman's Surgical Pathology.
- ii) Modern Surgical Pathology.

Gulshan Yadav, MD
Consultant Pathologist