

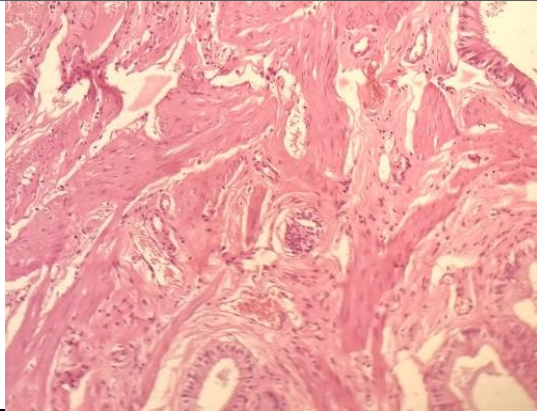
<b>Patient Name</b>	Mrs. RENU	<b>Client Name</b>	Kriti Hospital	<b>Specimen Received</b>	28-10-2019
<b>Age/Sex</b>	38 YRS/F			<b>Specimen Type</b>	Tissue
<b>Patient ID</b>	011910280048			<b>Collection Date</b>	28-10-2019
<b>Specimen ID</b>	MOLQ/B-2032/19			<b>Report Date</b>	31-10-2019

## SURGICAL PATHOLOGY REPORT

### Gall Bladder

#### DIAGNOSIS

**CHOLECYSTITIS AND CHOLELITHIASIS.**



#### **SPECIMEN**

Gall Bladder

#### **GROSS**

Received 8x2.3cm long gall bladder. Cut section shows stones.

#### **Microscopy**

Section examined shows ulcerative mucosa and Rokitansky-Aschoff sinus (irregularly shaped tubular structures lined by cuboidal lining epithelium with round to oval nucleus) with fibrocollagenous tissue and inflammatory cells (lymphocytes). NO granuloma and no malignant cells seen.

**Note :** All biopsy specimen will be stored for 15 (fifteen) days, block and slides for 5 (five) years only from the time of receipt at the laboratory. No request, for any of the above, will be entertained after the due date.

#### **Reference**

- i) Rosai and Ackerman's Surgical Pathology.
- ii) Modern Surgical Pathology.

**Gulshan Yadav, MD  
Consultant Pathologist**