

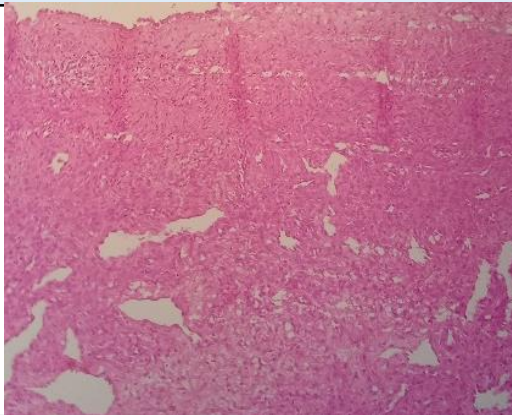
Patient Name	Mrs. KOMAL	Client Name	SRG Hospital, Kotla	Specimen Received	17-10-2019
Age/Sex	24 Years/Female			Specimen Type	Tissue
Patient ID	011910170178	Vihar		Collection Date	17-10-2019
Specimen ID	MOLQ/B-1976/19(2)			Report Date	31-10-2019

SURGICAL PATHOLOGY REPORT

Ovarian Cyst Wall

DIAGNOSIS

Simple Ovarian Cyst



SPECIMEN

Ovarian Cyst Wall

GROSS

Received 1x2 cm grayish white tissue piece.

Microscopy

Section examined shows cuboidal lining epithelium with small round nucleus with ovarian tissue and stromal cells .

Note : All biopsy specimen will be stored for 15 (fifteen)days, block and slides for 5(five) years only from the time of receipt at the laboratory. No request ,for any of the above ,will be entertained after the due date.

Reference

- i) Rosai and Ackerman's Surgical Pathology.
- ii) Modern Surgical Pathology.

**Gulshan Yadav, MD
Consultant Pathologist**