

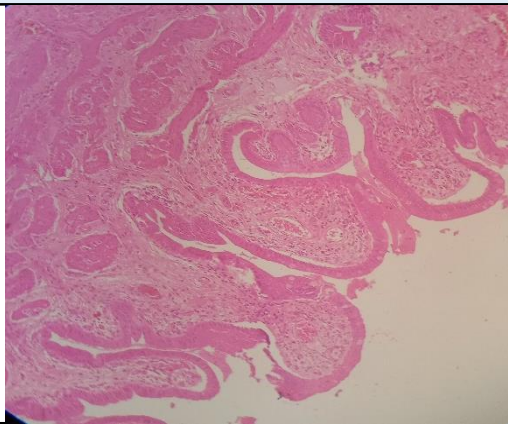
Patient Name	Mrs. BHAGWATI	Client Name	Cygnus SuperSpeciality	Specimen Received	25/10/19
Age/Sex	65 YRS/F	Hospital	Rewari	Specimen Type	Tissue
Patient ID	011910250166			Collection Date	25/10/19
Specimen ID	MOLQ/B-2025/19			Report Date	29/10/19

SURGICAL PATHOLOGY REPORT

Gall Bladder

DIAGNOSIS

CHOLECYSTITIS AND CHOLELITHIASIS.



SPECIMEN

Gall Bladder

GROSS

Received 4x2.9 cm long gall bladder. Cut section shows stones.


Microscopy

Section examined shows ulcerative mucosa and Rokitansky-Aschoff sinuses (irregularly shaped tubular structures lined by cuboidal lining epithelium with round to oval nucleus) with fibrocollagenous tissue and inflammatory cells (lymphocytes). No granuloma and no malignant cells seen.

Note : All biopsy specimen will be stored for 15 (fifteen) days, block and slides for 5 (five) years only from the time of receipt at the laboratory. No request, for any of the above, will be entertained after the due date.

Reference

- i) Rosai and Ackerman's Surgical Pathology.
- ii) Modern Surgical Pathology.


Gulshan Yadav, MD
Consultant Pathologist