

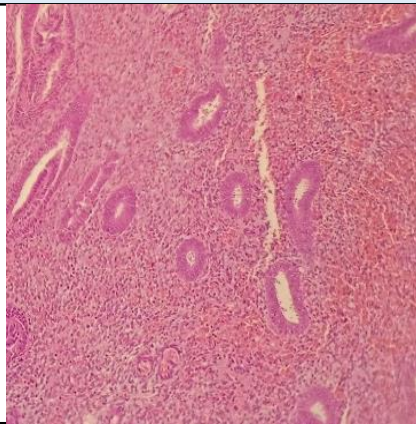
Patient Name	Mrs. ANITA DEVI	Client Name	Pushpanjali Hospital	Specimen Received	25/10/19
Age/Sex	51 YRS/F	(Rewari)		Specimen Type	Tissue
Patient ID	011910250175			Collection Date	25/10/19
Specimen ID	MOLQ/B-2028/19			Report Date	28/10/19

SURGICAL PATHOLOGY REPORT

Endometrium

DIAGNOSIS

PROLIFERATIVE PHASE



SPECIMEN

Endometrium

GROSS

Received multiple grayish white tissue piece.

Microscopy

Section examined shows small endometrial glands with columnar lining epithelium with round to oval nucleus. Stroma shows mononuclear inflammatory cells.

No granuloma seen. No malignant cells seen.

Note : All biopsy specimen will be stored for 15 (fifteen)days, block and slides for 5(five) years only from the time of receipt at the laboratory. No request ,for any of the above ,will be entertained after the due date.

Reference

- i) Rosai and Ackerman's Surgical Pathology.
- ii) Modern Surgical Pathology.

Gulshan Yadav, MD
Consultant Pathologist